

SLAP Lesions: Structure, Function, and Physical Therapy Diagnosis and Treatment

Peter A. Huijbregts, DPT, OCS, FAAOMPT

Abstract: This article describes the structure and function of the labral-bicipital complex. It also discusses incidence, classification, injury mechanisms, subjective and physical examination findings, and conservative treatment options for lesions to the labral-bicipital complex, also known as SLAP-lesions.

Key Words: Labrum, SLAP-Lesion, Structure, Function, Diagnosis, Treatment

The glenoid labrum receives only scant attention in classic anatomy texts: Spalteholz and Spanner¹ devote one line in their entire text to the labrum, describing it as a fibrocartilaginous structure reinforcing the glenoid cavity. Advances in arthroscopic surgery have, however, greatly increased our need for a more precise anatomic description. At the same time, these advances have enhanced our ability to diagnose, treat, and understand labral pathology², including lesions to the superior labrum and the tendon of the long head of the biceps. This labral-bicipital-complex is becoming increasingly recognized as an important stabilizing structure for the glenohumeral joint³.

In 1985, Andrews et al⁴ described antero-superior glenoid labrum tears in 83% of 73 throwing athletes evaluated

arthroscopically. In 1990, Snyder et al⁵ retrospectively reviewed 700 shoulder arthroscopies and identified 27 patients with an injury to the superior labrum; they established a classification system for these injuries and coined the acronym "SLAP"-lesion for Superior Labrum, Anterior and Posterior-lesion. In a later retrospective review, Snyder et al⁶ described 140 (6%) of 2375 patients treated arthroscopically as presenting with a SLAP-lesion. Maffet et al⁷ found arthroscopic abnormalities of the superior labrum in 206 (29%) of 712 patients. LaBan et al⁸ noted that 16% of all rotator cuff tears are accompanied by SLAP-lesions. Field and Savoie⁹ observed a 2% prevalence of two types of unstable SLAP-lesions during two years of arthroscopic shoulder surgeries. Based upon studies with a large series of patients undergoing an arthroscopy for various conditions, Bey et al¹⁰ estimated the prevalence of SLAP-lesions in this admittedly heterogeneous population to be between 6 and 11%.

The superior labrum-biceps complex plays an important role in the function of the glenohumeral joint. Accurate diagnosis of a SLAP-lesion may have important implications for pursuit of a conservative approach. This article describes the structure and function of the labrum-biceps

Address all correspondence and request for reprints to:
Peter A. Huijbregts
13826 South Meyers Road, #2034
Oregon City, OR 97045
peterh@pacifier.com

complex. It also discusses diagnosis using the means available to the physical therapist as well as conservative treatment options for SLAP-lesions. The goal of this article is to improve the therapist's understanding of SLAP-lesions to facilitate appropriate evaluation and treatment decisions.

Structure

Histology

A controversy exists as to the histology of the glenoid labrum¹¹. Both Spalteholz and Spanner¹ and Mileski and Snyder¹² described it as a fibrocartilaginous structure. Prodromos et al¹³ studied 38 cadaveric shoulders from individuals ranging in age from the second trimester of fetal life up to the tenth decade of life. They found that the labrum of newborns consisted of a cellular, vascular mesenchymal tissue. Most of the cells were undifferentiated, but there were chondrocytes present near the articular aspect of the labrum. The number of chondrocytes was found to increase with age: in all specimens over seven years old, the labrum was composed of fibrocartilaginous tissue, distinct from the fibrous shoulder capsule and the hyaline cartilage of the glenoid. They found no elastin fibers in the labrum of newborns, but there were thin elastin fibers sparsely distributed in the labra of individuals in the second decade of life or older. In contrast, Cooper et al¹⁴ studied 23 cadaveric shoulders from individuals between the fourth and the ninth decade of life and found the labrum to consist mainly of densely packed collagen bundles. The only fibrocartilage was located in a transition zone between the articular cartilage and the fibrous labrum. In a histologic analysis of 6 normal superior labra, Kreitner et al¹⁵ found poorly vascularized dense bundles of fibrous connective tissue; they described as well a transitional zone between the normal labral tissue and the hyaline cartilage composed of fibrocartilage with an increased glycosaminoglycan content.

Vascularization

The labrum receives its blood supply from the suprascapular artery, the circumflex scapular branch of the subscapular artery and the posterior circumflex humeral artery¹⁴. Controversy also exists regarding the extent of vascularity of the labrum¹¹. Cooper et al¹⁴ found vascular penetration to be limited to the peripheral attachment of the labrum to the shoulder capsule. No vessels were found penetrating the central part of the labrum from the underlying glenoid bone. Superior and antero-superior portions of the labrum were found to be less vascular than the posterior and inferior portions¹⁴. In contrast, Prodromos et al¹³ found no distinct vascular and avascular areas and they described blood vessels even at the central edge of the labrum; they did note a decrease of vascularity with increasing age.

Anatomy of the superior labrum

Morphology of the superior labrum differs quite distinctly from that of the inferior labrum^{14,16}. The inferior labrum is a rounded extension of the articular cartilage consisting of inelastic fibrous¹⁴ (or possibly fibrocartilaginous^{1,12,13}) tissue; in non-pathological circumstances, it is firm and unmoving¹⁶. The superior and antero-superior labrum is described as meniscal, triangular in cross section, with a loose attachment to the glenoid¹⁴. The articular cartilage actually extends over the edge of the glenoid rim in the 12 o'clock position of the glenoid cavity¹⁴. The antero-superior labrum frequently inserts into the fibers of the medial (MGHL) or inferior glenohumeral ligament (IGHL) rather than into the glenoid margin⁶. Cooper et al¹⁴ found the antero-superior labrum to be loosely attached to the glenoid rim by thin capsular tissue in 5 of 11 cadaveric shoulders, firmly attached in 2, and not at all attached in 4. Other authors also described this physiologic detachment of the antero-superior labrum and called it the sublabral hole, foramen, or recess^{6,15,17}.

Smith et al¹⁷ studied 26 cadaveric shoulders from subjects between 26 and 79 years old and found a sublabral recess in 19 (73%) of the shoulders studied. In 16 shoulders, the recess was located antero-superiorly, and in the remaining 3 at the level of the insertion of the tendon of the long head of the biceps. Kreitner et al¹⁵ studied 17 cadaveric shoulders from subjects between 64 and 87 years old and found a sublabral recess in 12 (71%). In 7 shoulders, the recess was located antero-superiorly, in 4 more central, at the level of the biceps insertion, and in 1 shoulder, through the entire base of the superior labrum. It has been postulated that this sublabral foramen is a degenerative lesion resulting from pull of the glenohumeral ligaments and the biceps tendon¹⁷. Smith et al¹⁷ did find a weak correlation between the age of their specimens and the depth of the sublabral recess possibly supporting this theory, but neither Smith et al¹⁷ nor Kreitner et al¹⁵ found histological evidence of a traumatic origin for the sublabral foramina. Schmitz and Ciullo¹⁸ reported a 12% incidence of this sublabral hole in 200 consecutive shoulder arthroscopies. The importance of this sublabral foramen and another anatomic variant called the Buford complex, in which the antero-superior labrum is absent and a thick MGHL takes its place, is that these variants may mimic a superior labral lesion¹⁵.

The postero-superior labrum is anchored at the 10 o'clock position of the glenoid rim with the labrum either rounded as described for the inferior portion or more triangular similar to the antero-superior labrum¹⁴. Pal et al¹⁹, in their gross anatomy study of 24 cadaveric shoulders, found that in 16, the postero-superior margin of the glenoid was deficient and actually replaced by the tendon of the biceps. They noted that the joint cavity in these specimens extended between the tendon and the margin of

the glenoid with a small postero-superior crescentic facet covered with hyaline cartilage separated from the rest of the joint cavity by a faint ridge. Histologic analysis to substantiate these findings, however, was not performed.

Anatomy of the tendon of the long head of the biceps

The tendon of the long head of the biceps is usually described as inserting into the supraglenoid tubercle²⁰. At the 12 o'clock position of the glenoid, this tubercle is located approximately 5 mm medial to the superior glenoid rim^{12,20}. Cooper et al¹⁴ found that the superior labrum inserts directly into the biceps tendon distal to its insertion and that collagen fibers of the biceps and labrum intermingle in this area with some labral collagen fibers attaching also to the supraglenoid tubercle. Upon dissection, Pal et al¹⁹ found that in 6 (25%) of 24 cadaveric shoulders, the major portion of the biceps tendon was attached to the supraglenoid tubercle with a portion of the tendon continuous with the superior labrum. In 16 (67%) shoulders, the major portion of the tendon inserted in and even replaced the postero-superior labrum with only a thin slip of the tendon inserting into the tubercle; in 2 of these 16 shoulders, this slip was even absent. In 2 of the 24 shoulders, the biceps tendon was found to blend with both the postero-superior and the antero-superior labrum. Vangsness et al²⁰ did an anatomical and histologic study on 100 cadaveric shoulders from subjects aged between the third to the ninth decade. They found that in all shoulders, 40 to 60% of the biceps tendon inserted into the supraglenoid tubercle. The remaining biceps tendon fibers inserted into the labrum, either all posteriorly (22%), mainly posteriorly with a small contribution to the anterior labrum (33%), equally anteriorly and posteriorly (37%), or mainly into the anterior labrum (8%).

Function

Labrum

The surface area of the humeral head is approximately 3 to 4 times that of the glenoid cavity¹⁶. The maximum diameter of the glenoid is approximately 75% of the maximum diameter of the humeral head in an infero-superior direction, but it adds up to only 60% of the humeral head diameter in an antero-posterior direction; at any point in time, only 25-30% of the humeral head is actually in contact with the glenoid cavity¹⁶. The humeral head articulates with the glenoid and possibly with the capsulolabral structures. Thus, the labrum increases total surface area available for articulation with the humeral head¹⁶.

Howell and Galinat²¹ studied 25 skeletally mature cadaveric shoulders. They found a maximum depth of 8.8+/-1.7 mm for the central portion of the glenoid in an infero-superior direction; contribution of the labrum to that

depth was 48+/-8%. In the antero-posterior direction, the maximum depth of the socket was 5.0+/-1.6 mm with 51+/-10% contributed by the labrum. In the narrowest portion of the labrum, the total glenoid depth was only 3.5+/-1.2 mm with a labral contribution of 57+/-12%. All values calculated for depth were normalized based on a humeral head with a diameter of 44 mm.

The labrum obviously contributes significantly to glenoid socket depth. Similar to the force of gravity compressing a car tire against the road and preventing it from rolling up and over a chock block, the muscular envelope of the shoulder may compress the humeral head within the socket. This prevents the head from rolling up and over the chock block formed by the labrum²¹. Labral damage disrupts the circular configuration and hoop stresses generated within the labrum rendering this chock block mechanism less effective²¹.

The labrum also acts like a seal: labral injury may result in a loss of negative intra-articular pressure, further reducing joint stability¹⁶. Finally, the labrum allows for attachment of the glenohumeral ligaments to the glenoid¹⁶. The superior glenohumeral ligament (SGHL) originates from the supraglenoid tubercle and the adjacent labrum¹¹. The MGHL originates adjacent to the SGHL from the glenoid neck and antero-superior labrum^{11,16}. The IGHL blends into the inferior labrum with its anterior band attached to the glenoid rim and labrum at the antero-inferior 4 o'clock position^{14,16}. What, however, is the specific biomechanical function of the superior labrum-biceps-complex?

Labral-bicipital complex

Warner and McMahon²² studied seven patients with a rupture of the tendon of the long head of the biceps. They excluded patients with rotator cuff involvement through clinical examination, arthroscopic evaluation, and MR imaging. In vivo radiographs were taken with the arms positioned at 0, 45, 90, and 120° of scapular plane abduction. Comparing the involved to the uninvolved shoulder, the authors found a significant ($P < 0.01$) increase in superior translation in the involved shoulder in all positions except at 0° of abduction. Superior translation was 2.1+/-1.6 mm for the involved versus -0.1+/-0.4 mm for the uninvolved shoulder at 45°, 2.4+/-0.8 mm versus 0.1+/-0.4 mm at 90°, and 2.9+/-1.6 mm versus 0.6+/-0.8 mm at 120° of abduction. Having been careful to rule out rotator cuff involvement, the authors stated that the increase in superior translation observed during scapular plane abduction was due to loss of the action of the tendon of the long head of the biceps. They also stated that decreased biceps function and the resultant increased superior translation of the humeral head might contribute to the development of subacromial impingement in the presence of a type II or III (hook-shaped) acromion (conform the Bigliani classification).

Itoi et al²³ studied the contribution of both the short and the long head of the biceps to anterior stability. Leaving the rotator cuff and capsule intact and replacing the long and short head of the biceps with springs, they mounted 13 cadaveric shoulders in a position to simulate what, on visual inspection of the illustration in their article, appears to be 60° of glenohumeral scapular plane abduction. They monitored anterior translation in response to application of a 1.5 kg anterior force applied to the proximal humerus in 60, 90, and 120° of external rotation. The capsule was left intact, vented, or with a lesion of the antero-inferior capsule intended to simulate a Bankart lesion. Anterior displacement was significantly reduced in shoulders with an intact capsule by loading the long head of the biceps with either 1.5 or 3 kg at both 60 (P<0.0001) and 90 (P=0.0011) but not at 120° of external rotation. Loading the short head had similar effects at both 60 (P<0.0001) and 90 (P=0.0003), but again not at 120°. Venting the capsule made no difference in displacement, but after creation of a Bankart lesion, both long head and short head loading significantly (P<0.0001) decreased anterior displacement at all positions of external rotation, including 120°. The authors stated that both the long and the short head of the biceps function as anterior stabilizers of the glenohumeral joint with an increasing role in unstable shoulders.

Pagnani et al²⁴ measured antero-posterior and supero-inferior translation as a result of an anterior, posterior, inferior, and superior 55 N force in 7 cadaveric shoulders with and without a 55 N force applied to the tendon of the long head of the biceps. Shoulder capsules were vented prior to testing to eliminate the effects of negative intra-articular pressure. A constant 22 N compressive load was applied to the shoulders. Shoulders with evidence of rotator cuff tear and degenerative joint disease were excluded. The shoulders were tested in seven positions: 0, 45, and 90° of scapular plane abduction accompanied by neutral, 30° of internal, and 30° of external rotation. At 0° of abduction, only neutral rotation was tested.

Translation in a shoulder with an intact labrum was compared to a situation in which the antero-superior labrum with the glenoid attachments of the SGHL and MGHL were detached. The shoulder with an intact labrum was also compared to one in which this lesion was extended equally far posteriorly, affecting the biceps attachment to the labrum. The antero-superior lesion had no significant effect on translation, with or without biceps tension. With the complete lesion, there was a significant (P=0.004) increase in anterior translation of 4.0 mm at 90° of elevation and internal rotation. At 45°, there was a significant increase in anterior translation of 6.0 mm in neutral rotation and of 6.3 mm in internal rotation (both P<0.0001). Inferior translation increased significantly with 1.9 to 2.5 mm in all positions of rotation. Application of biceps tension in the presence of the complete lesion reduced

translation, but it remained significantly increased as compared to one without the lesion. The authors stated that superior labral lesions involving the supraglenoid insertion of the biceps would increase glenohumeral translation in multiple directions, especially in the lower and middle ranges of scapular plane abduction. They noted this usually is not associated with overt instability, yet patients may report a sensation of looseness or slipping of the shoulder with subtle increases of translation upon physical examination. They also noted that the observed stabilizing function of the biceps may be further impaired in vivo by inhibition due to pain or unfavorable length/tension relationships due to loosening of the proximal attachment of the biceps, resulting in greater increases in translation.

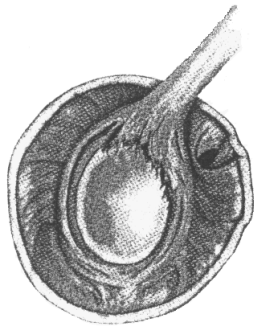
Rodosky et al²⁵ used 7 cadaveric vented shoulders from subjects with a mean age of 55.6 years to determine the effect of the level of contraction of the long head of the biceps on torsional rigidity of the shoulder and strain in the anterior-superior band of the IGHL. Torsional rigidity is the torque required to produce a unit of angular twist; i.e., it is a measure of the ability of the shoulder to withstand excessive rotational forces e.g. as experienced during the late cocking position of an overhead throw. Rotator cuff forces were simulated based on EMG measurements of muscle activity during late cocking and based on cross-sectional area measurements of the rotator cuff muscles on the specimens. Each shoulder was tested at 0, 25, 50, 75, and 100% of the extrapolated maximum force of the long head of the biceps. In normal shoulders, torsional rigidity increased with increasing biceps force up to a 32% increase at 100% biceps force; strain in the anterior band of the IGHL remained virtually constant despite increasing external rotation forces applied to the glenohumeral joint in the presence of increasing biceps muscle force. Measurements were repeated after the superior labrum, including the origin of the long head of the biceps, was subperiosteally stripped from the 10 o'clock to the 2 o'clock position. Mean torsional rigidity was found to be 19% higher in normal shoulders at 0% biceps force, tapering off to an 11% difference at 100% biceps force (P<0.01). Strain in the IGHL was found to be 120% higher at 0% biceps force with the experimentally induced superior labral lesion. This strain lessened as biceps force was increased; a 102% increase in IGHL strain occurred at 100% biceps muscle force. The authors stated that the long head of the biceps contributes to anterior shoulder stability by increasing torsional rigidity of the shoulder and by reducing strain on the IGHL.

Classification

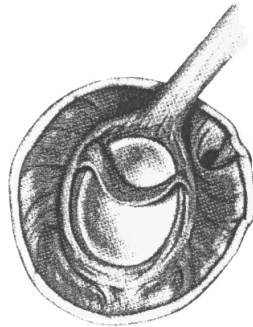
Snyder et al⁵ were the first to describe a classification system for injuries involving the superior part of the glenoid labrum, that begin posteriorly and extend

anteriorly, stopping at or above the mid-glenoid notch. They coined the term SLAP-lesion or Superior Labrum Anterior to Posterior-lesion and identified four different types of SLAP-lesions (Figure 1):

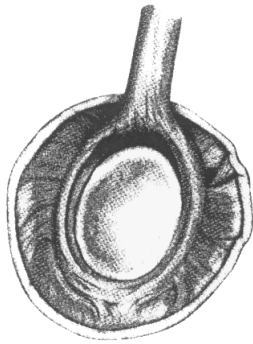
- Type I: There is marked fraying of the labrum with a degenerative appearance. The peripheral labral edge



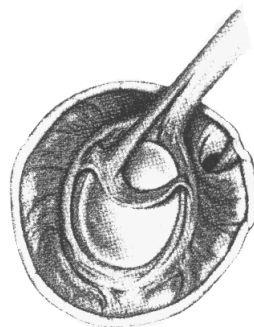
Type I SLAP lesion with frayed and degenerated superior labrum



Type III SLAP lesion with bucket-handle tearing of superior labrum. Remaining labral tissue remains anchored to glenoid rim.



Type II SLAP lesion with detachment of superior labrum and biceps tendon from glenoid rim.



Type IV SLAP lesion with extension of displaced bucket-handle labral tear into biceps tendon.

Fig. 1: Type I-IV SLAP-lesions. Reprinted with permission from Snyder SJ, Banas MP, Karzel RP. An analysis of 140 injuries to the superior glenoid labrum. *J Shoulder Elbow Surg* 1995;4:243-48.

remains firmly attached to the glenoid and the attachment of the biceps tendon to the labrum is intact as well.

- Type II: Fraying and degenerative changes are similar to the changes seen in a type I lesion, but, in addition, the superior labrum and the biceps tendon are stripped away from the underlying glenoid, resulting in an unstable labral-biceps anchor arching away from the glenoid.
- Type III: There is an antero-posterior bucket handle tear in the superior labrum. The more central portion of

this tear is displaceable into the joint, but the peripheral portion remains attached to the underlying glenoid and to the tendon of the long head of the biceps. The biceps tendon is intact.

- Type IV: In type IV lesions, there is a bucket handle tear in the superior labrum similar to the type III lesion, but this tear extends into the biceps tendon. This partial biceps tendon tear can displace together with the labral flap into the joint cavity.

In their original article, Snyder et al⁵ stated that a detachment of the superior labrum from the peripheral aspect of the glenoid should invariably be considered pathological, i.e., diagnosed and treated as a type II SLAP-lesion. This is not supported by the anatomical descriptions of the superior labrum discussed earlier. Mileski and Snyder¹² altered the original description by noting that findings consistent with a SLAP-lesion include:

- signs of hemorrhage or granulation tissue beneath the biceps tendon and superior labrum,
- presence of a space between the articular cartilage margin of the glenoid and the attachment of the labrum and biceps anchor,
- arching away of the superior labral mechanism from the glenoid for more than 3 to 4 mm, when traction is applied to the biceps tendon.

Maffet et al⁷ retrospectively reviewed 712 arthroscopic shoulder surgeries and identified 206 patients with abnormalities of the superior labrum. Isolated minor fraying was found in 122 patients, consistent with the description of a type I SLAP-lesion and left untreated. Of the remaining 84 patients, 52 (62%) fit into the established classification system. They expanded the original system with three more categories to be able to classify the remaining patients:

- Type V: This lesion has an anterior-inferior Bankart lesion that continues superiorly and includes separation of the biceps tendon from the glenoid margin.
- Type VI: There is an unstable flap tear of the labrum, in addition to the biceps tendon separation.
- Type VII: The separation of the superior labrum-biceps tendon-complex extends anteriorly beneath the MGHL.

Diagnosis

Diagnosis of a SLAP-lesion is based on patient history (injury mechanism, symptoms), clinical tests, diagnostic imaging, and arthroscopic evaluation. Possible arthroscopic findings have been discussed above in Anatomy and Classification. Diagnostic imaging is outside of the scope of this article.

Injury mechanism

During arthroscopic surgery, Andrews et al⁴ showed that electrical stimulation to the biceps in five of their patients raised the superior portion of the labrum off the

glenoid, while simultaneously compressing the humeral head into the glenoid cavity. They also reported on a biomechanical analysis of the throwing movement and calculated moments in excess of 600 inch lbs (69 Nm) produced in the elbow during the acceleration phase of the overhead throw. They hypothesized that forces imparted by the biceps tendon, particularly during the follow-through phase might cause mechanical disruption of the superior labrum, as the biceps eccentrically contracts to decelerate the elbow as well as to provide compressive force to stabilize the glenohumeral joint. This mechanism of injury may be even more prevalent in unstable shoulders: Glousman et al²⁶ found a significant increase in electromyographic activity of the biceps during the acceleration phase in throwing athletes with glenohumeral instability.

In their initial study of 27 patients, Snyder et al⁵ described the main mechanism of injury in 13 patients to be a fall onto an outstretched arm held in abduction and slight forward flexion at the moment of impact. A second mechanism of injury was traction to the arm. This could be the result of a sudden pull (six patients), or it could be due to a throwing or other overhead motion (two patients). In six patients, there was an insidious onset. The authors postulated that a SLAP-lesion is caused by the combination of a proximal subluxation of the humeral head and a compression force on the superior joint surface causing the labrum and biceps tendon to be pinched between the humeral head and the glenoid. They stated that this might cause a traumatic disruption to these tissues and possibly even a compression fracture to the superior humeral head. Further abduction of the arm may cause a type III or IV lesion in the presence of a meniscoid glenoid labrum²⁷. They also suspected that the traction-type injury might be further aggravated by a strong reflex contraction of the biceps.

In their study of 140 cases⁶, Snyder et al found 43 patients to have fallen or received a direct blow to the shoulder. A glenohumeral subluxation or dislocation was the cause in 27 patients, while 23 started having problems when lifting a heavy object, 19 had an insidious onset, and in 16 the complaints started as a result of overhead or racquet sports. The authors were unable to prove the assumptions made in their first study regarding mechanism and type of injury⁵: no statistical correlation was found between type of SLAP-lesion and mechanism of injury.

Maffet et al⁷ recorded traction injuries (e.g., traumatic dislocation, abduction-external rotation while throwing or swinging a heavy hammer, anterior traction with waterskiing, or upward traction when grabbing overhead onto something to halt a fall) as the mechanism of injury in 66% of their patients. Inferiorly directed traction was most common. They found instability in 44.5% of patients during anaesthesia but made no assumptions regarding the relationship between SLAP-lesions and

glenohumeral instability.

Cordasco et al²⁸ also noted traction injuries to be the most prevalent cause of SLAP-lesions, as 25 of their 27 patients were involved in overhead sports. They found instability in 70% of their patients under anaesthesia and stated that labral tears should be considered the result of instability, rather than isolated, primary lesions. In this study, indication for surgery was no response to an average of 24 months of conservative therapy: this long period between initial onset of complaints and surgery does not seem to exclude instability developing as a result of changed glenohumeral mechanics after the SLAP-lesion occurred.

To clarify the importance of inferior glenohumeral subluxation in the production of type II SLAP-lesions, Bey et al¹⁰ applied traction to the long head of the biceps of 16 cadaveric shoulders (age 62+/-7.2 years). Eight shoulders were in a reduced position and the other eight in a 20 mm inferiorly subluxed position. The number of SLAP-lesions produced in the inferiorly subluxed group (7/8) was significantly ($P=0.03$) higher than in the reduced group (2/8). They hypothesized that inferior subluxation caused the biceps tendon to be directed more inferiorly at its insertion, increasing the chance for a type II SLAP-lesion. They were unsure whether the amount of subluxation required for the experimental production of SLAP-lesions would actually result in clinical symptoms of shoulder instability. They agreed with Snyder et al⁵ that it is unlikely that all types of SLAP-lesion are caused by the same mechanism: type II lesions are likely produced by traction, whereas type I, III, and IV lesions are more likely to be caused by a combination of shear and compression in the glenohumeral joint.

Subjective symptoms

When attempting to describe the subjective symptoms specific to a SLAP-lesion, we are faced with a problem. Descriptions in the literature are seldom of patients with isolated SLAP-lesions, either because of a prolonged time before appropriate diagnosis, in which secondary problems have had a chance to develop, or because of the extent of the original injury, which involved multiple structures about the shoulder. In their original study of 27 patients, Snyder et al⁵ found a partial rotator cuff (RC) tear in seven, a full-thickness tear in four, anterior instability in four, humeral head chondromalacia or an indentation fracture in seven, and acromio-clavicular (AC) arthritis in three patients. In their study of 140 patients⁶ there were 40 patients with partial RC tears, 15 with full-thickness tears, 31 with Bankart-lesions, 22 with AC degeneration, and 14 with glenohumeral chondromalacia. Andrews et al⁴ noted partial RC tears in 45% of 73 throwing athletes with superior labral lesions. Maffet et al⁷ reported 32 partial, 4 full-thickness, and 4 RC interval tears in their 84 patients.

Shoulder pain appears to be the most common complaint of patients with SLAP-lesions. Snyder et al^{5,6} reported shoulder pain in 100% of patients in both studies. They also reported shoulder pain in all 40 patients with an isolated SLAP-lesion⁶. Maffet et al⁷ reported non-specific posterior shoulder pain in 99% and aching in 21% of their patients. Andrews et al⁴ reported an increase in pain with throwing in 95% of the throwing athletes treated. Glasgow et al² stated that a sudden inability to perform overhead throwing or striking activities due to pain without reference to a specific injury, in combination with the presence of a palpable click on testing, is highly suggestive of a labral tear in overhead athletes. Pain is most common with overhead activities^{5,12} but can also occur with lying on the affected shoulder or other unspecified ADL¹².

Mechanical symptoms also appear to be common in this patient population. Andrews et al⁴ reported popping or catching with throwing in 47% of their patients. Symptoms of catching, locking, popping, or grinding were present in 12 of 27 patients⁵, and in 49% of 140 patients⁶ in the studies by Snyder et al^{5,6}. Of the 40 patients with isolated SLAP-lesions in the later study⁶ 70% had said mechanical symptoms. Patients may also complain of the sensation of the “shoulder going out”^{7,8,18}. This feeling results from labral tears that become interposed between the humeral head and the glenoid^{7,18}. Patients may report a need to “move (the labral fragment) around to get it back in place”¹¹.

Andrews et al⁴ noted subjective reports of limited ROM in only 3% of patients, whereas Maffet et al⁷ found this in 12% of their patients. Decreased strength was a complaint in 18% of the patients in the study by Maffet et al⁷.

Clinical tests

When trying to describe physical examination findings specific to patients with SLAP-lesions, we are again faced with the problem that SLAP-lesions described in the literature are seldom isolated lesions. In recent literature, however, there has been a plethora of reports describing sensitivity and specificity of clinical tests to detect SLAP-lesions^{3,29-33}.

Kibler³ described the *anterior slide test* (Figure 2). The patient is positioned in either sitting or standing, with the hand on the hip and the thumb pointing posteriorly. The examiner places one hand across the top of the shoulder from a posterior direction with the last part of the index finger extending over the anterior aspect of the acromion at the glenohumeral joint. The examiner's other hand is placed behind the elbow, and an anterior and slightly superiorly directed force is applied to the elbow and the upper arm. The examiner asks the patient to push back against this force. The rationale for this test is to create an anterior and superior translation of the head of the humerus on the glenoid, which should

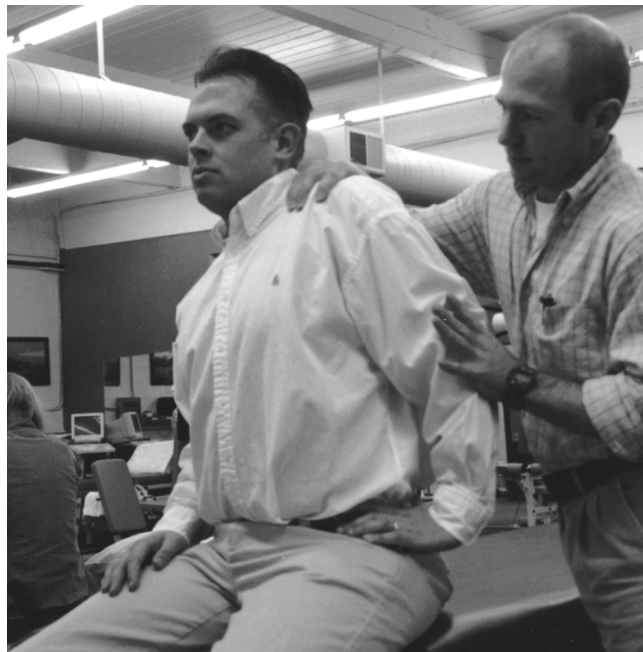

Fig. 2: Anterior slide test. Adapted from Kibler WB. Specificity and sensitivity of the anterior slide test in throwing athletes with superior glenoid labral tears. Arthroscopy 1995;11:296-300.

normally be resisted by an intact superior labrum, biceps, and superior glenohumeral complex. According to Kibler, this test is intended to detect lesions of the superior glenoid labrum, with or without a movable free fragment. The test is considered positive in case of pain at the anterior shoulder under the examiner's hand, and/or production of a pop or click in the same area. The test is also positive if it reproduces the symptoms the patient normally notes during overhead activity.

Kibler performed the test on three groups of throwing athletes with either confirmed superior labral tears or partial thickness RC tears and/or superior labral tears or antero-inferior instability and/or superior labral tears. He also used one group of throwing athletes without complaints but with an internal rotation (IR) deficit of more than 25°, and one group of non-overhead throwing soccer athletes. Sensitivity was found to be 78.4% with a specificity of 91.5%. The author noted that the test might be more useful with a concomitant RC injury than with a concomitant instability. Decreased IR, frequently found in throwing athletes, only caused a low (11%) incidence of false-positive tests. Even though specificity was found to be high, Kibler stated that sensitivity was insufficient to warrant using this test as a sole diagnostic criterion.

Liu et al³⁰ did a prospective evaluation of the diagnostic value of what they named the *crank test* (Figure 3). Their protocol calls for the test to be performed first

in sitting and then with the patient supine. The arm is elevated to 160° in the scapular plane. A joint load is applied by the examiner along the long axis of the humerus with one hand, while with the other hand the examiner performs external (ER) and internal rotation. The test is

the patient is horizontally flexed across the chest. The elbow is extended and the forearm pronated (thumb down). This may cause pain in the area of the bicipital groove with or without an audible or palpable click. The test is subsequently repeated with the forearm supinated (thumb

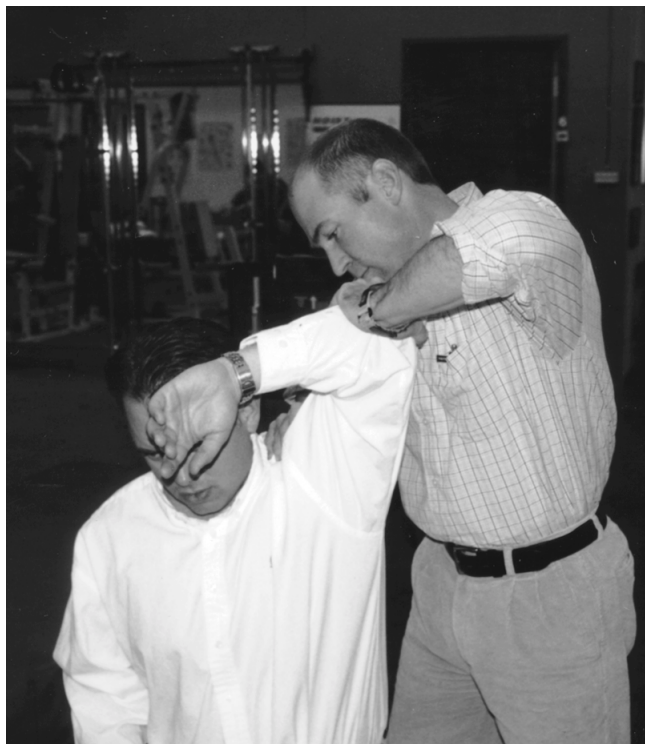


Fig. 3: Crank test. Adapted from Liu SH, Henry MH, Nuccion SL. A prospective evaluation of a new physical examination in predicting glenoid labral tears. Am J Sports Med 1996;24:721-25.

considered positive if pain is reproduced with or without a click, or if symptoms (usually pain or catching felt by the patient during work or athletic activities) are reproduced. Pain is usually felt during the ER portion of the test. A positive test is positive in both sitting and in supine. The authors studied 62 patients excluding patients with a history of dislocation or RC weakness clinically indicative of an RC tear. Pre-operatively there were 31 patients diagnosed with RC tendinitis and 31 with labral tears; intra-operatively 32 patients were found to have a labral tear. All tears involved the superior labrum; two extended postero-inferiorly, six antero-inferiorly. The sensitivity of the crank test was determined to be 91%, sensitivity 93%, positive predictive value 94%, and negative predictive value 90%. The authors stated that the crank test could be used as a sole physical examination test highly accurate for the diagnosis of labral tears.

Berg and Ciullo described the *SLAP prehension test* (Figure 4), initially without³⁴ but later with data on sensitivity²⁹. With the patient seated or standing, the arm of

up). This should cause a decrease in the reported pain. If there is no decrease, the test is considered negative or indeterminate. The rationale behind the test is that elbow extension and forearm pronation put tension on the tendon of the long head of the biceps. As scapular protraction becomes limited due to the clavicle, further horizontal flexion will entrap an unstable labral-bicipital-complex between the glenoid and the humeral head causing pain. Tension on the biceps is reduced with supination of the forearm allowing the labrum and biceps to reduce resulting in a decrease in pain reported. This mechanism was arthroscopically confirmed in two patients. The authors retrospectively reviewed 66 patients with arthroscopically confirmed SLAP-lesions. The SLAP prehension test was found to be sensitive in only 50% of stable, i.e., type I-lesions. Sensitivity for unstable SLAP-lesions (type II, III, and IV) was found to be 87.5%. The authors recommended further study into specificity and accuracy of the test but pointed out that this test did have promise for distinguishing stable from unstable SLAP-

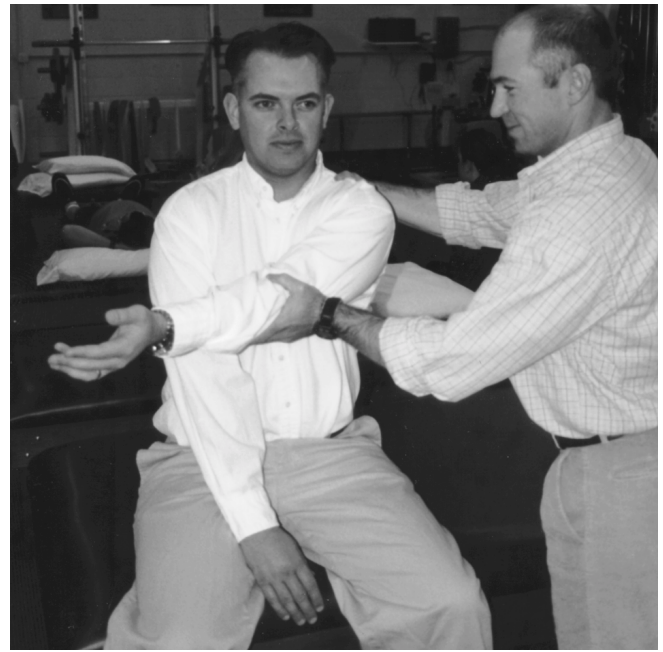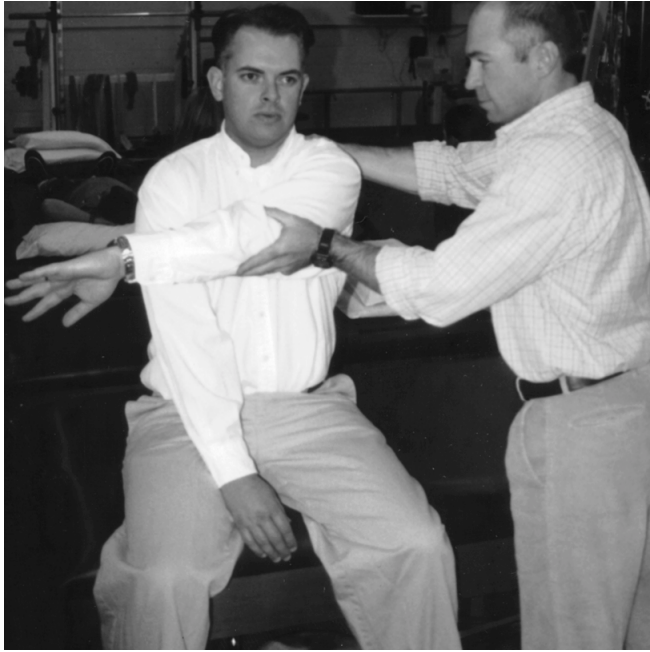


Fig. 4: SLAP prehension test. Adapted from Berg EE, Ciullo JV. A clinical test for superior glenoid labral or "SLAP" lesions. *Clin J Sports Med* 1998;8:121-23.

lesions, which may be important for management, because type I SLAP-lesions may not be clinically significant^{7,29}.

O'Brien et al³² described the *active compression test* (Figure 5) to diagnose both labral tears and AC abnormalities. The patient flexes the arm forward to 90° with the elbow fully extended and then adducts the arm 10-15° medial to the sagittal plane. With the arm internally rotated, such that the thumb points down, the patient is asked to hold an isometric flexion against the resistance provided by the examiner standing behind the patient. The test is repeated with the arm in the same position and the forearm fully supinated. A test is considered positive when pain is elicited by the first maneuver and is reduced or even eliminated with the second maneuver. Pain localized to the AC joint or on the top of the shoulder is considered diagnostic of AC abnormality; pain or painful clicking, described as inside the glenohumeral joint, is considered diagnostic for labral abnormality. A prospective evaluation of 268 patients showed a sensitivity of 100%, specificity of 98.5%, positive predictive value of 94.6%, and negative predictive value of 100% for the test when used to diagnose labral tears. Values for diagnosis of AC abnormalities were 100%, 96.6%, 88.7%, and 100%, respectively. The authors did not mention whether this test is specific to a specific type of labral tear, yet they offered a rationale similar to Berg and Ciullo's³⁴ to explain its use as a labral test.

Excluding patients with glenohumeral instability,

Mimori et al³¹ prospectively evaluated a *provocation test for tears of the superior labrum* in 32 throwing athletes (Figure 6). The test is performed in sitting with the shoulder in 90-100° of abduction. The arm is then passively externally rotated maximally with the forearm either in maximum pronation or in maximum supination. The test is considered positive when pain is provoked only in the pronated position or when pain is more severe in this position. Rationale for the test again is based on differences in biceps tension due to pronation or supination. Test results were compared with findings on MR arthrography in 32 and arthroscopy in 15 patients. A type II SLAP-lesion was arthroscopically confirmed in 11 patients. Sensitivity for superior labral detachment (confirmed in 22 patients) was 100%; specificity was found to be 90%. The authors also studied the crank test described by Liu et al³⁰ and found sensitivity and specificity of 83% and 100%, respectively, for diagnosing superior labral detachment. The authors doubted the usefulness of their test for diagnosing type I-lesions.

Kim et al³³ used the studies by Glousman et al²⁶ and Rodosky et al²⁵ on the role of the biceps in increasing torsional rigidity and anterior stability of the shoulder to develop the *biceps load test* (Figure 7). The test is meant to determine whether there is a concomitant SLAP-lesion in shoulders with recurrent anterior dislocations. The patient is supine and the examiner sits next to the patient on the affected side. With the shoulder abducted to 90° and the forearm supinated, an anterior apprehen-

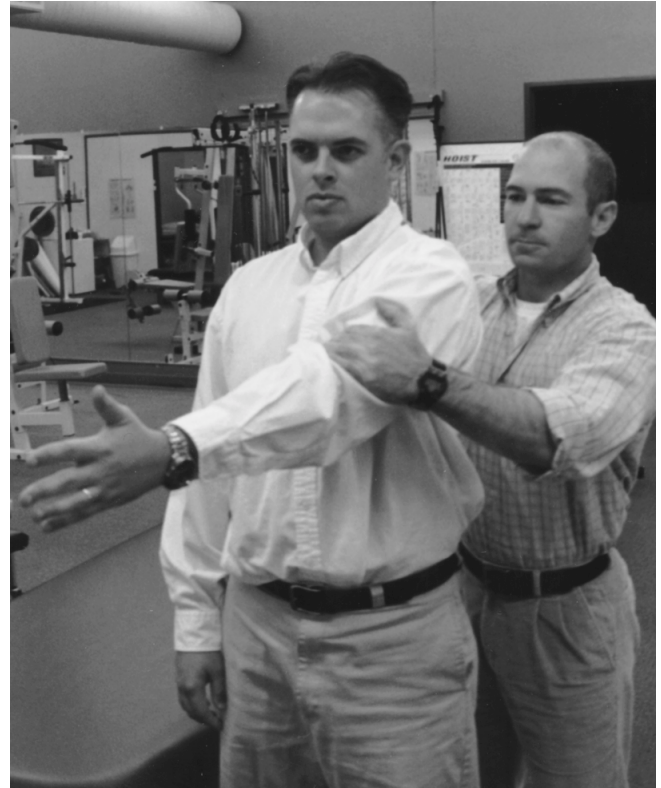


Fig. 5: Active compression test. Adapted from O'Brien SJ, Pagnani MJ, Fealy S, McGlynn SR, Wilson JB. The active compression test: A new and effective test for diagnosing labral tears and acromioclavicular joint abnormality. Am J Sports Med 1998;26:610-13.

sion test is performed by externally rotating the shoulder. At the point of apprehension, the patient is asked to isometrically contract the biceps. Decreased pain indicates an intact biceps-labral complex. The test is positive if apprehension is not changed or if the shoulder becomes more painful. In their study of 75 patients with recurrent anterior dislocations, 12 of whom had arthroscopically confirmed type II-SLAP lesions, sensitivity of the test was determined to be 90.9%, specificity 96.9%, positive predictive value 83%, and negative predictive value 98%.

The literature reviewed mentions a number of other physical signs and tests usually without reference to accuracy. These tests may be helpful, nonetheless, in diagnosing a SLAP-lesion. Andrews et al⁴ found popping or catching in 79% of their patients, especially in full flexion or abduction. Snyder et al⁶ found crepitations with ROM in 27% of their patients with an isolated SLAP-lesion. Mileski and Snyder¹² reported audible popping or snapping in 43% of 23 patients with an isolated SLAP-lesion. Biceps tension tests are frequently positive^{5,6,8,9,12}: Snyder et al⁶ found 40% positive biceps tension signs in 40 patients with isolated SLAP-lesions and Mileski and Snyder¹² found 35% positives in a similar group of 23 patients. Kim et al³³ found

a sensitivity of 72.7%, a specificity of 78.1%, a positive predictive value of 36%, and a negative predictive value of 94% for a biceps tension test in their population of patients with recurrent anterior dislocations with concomitant type-II SLAP-lesions. In three studies with patients with isolated superior labrum injuries, the anterior apprehension test was found to be positive in 27%⁶, 39%¹², and 52%²⁸. Impingement tests were positive in 60% of the patients with isolated lesions in a study by Snyder et al⁶. The Neer sign was positive in 52%, and the Hawkins sign in 35% in a similar group in the study by Mileski and Snyder¹²; the same study found pain on resisted supraspinatus testing in 35% of patients¹².

With the clunk test, the patient is supine with the arm fully abducted and one hand of the examiner placed posteriorly on the head of the humerus. The examiner then externally rotates the humerus while applying an anteriorly directed force on the humeral head. A clunk or grinding is indicative of a labral tear³⁵. With the compression-rotation test^{5,6,8,12}, the patient is again positioned supine with the shoulder 90° abducted and the elbow 90° bent; under axial compression the humerus is rotated in an attempt to trap the torn labrum; labral tears may be felt to catch or snap with this test⁶.

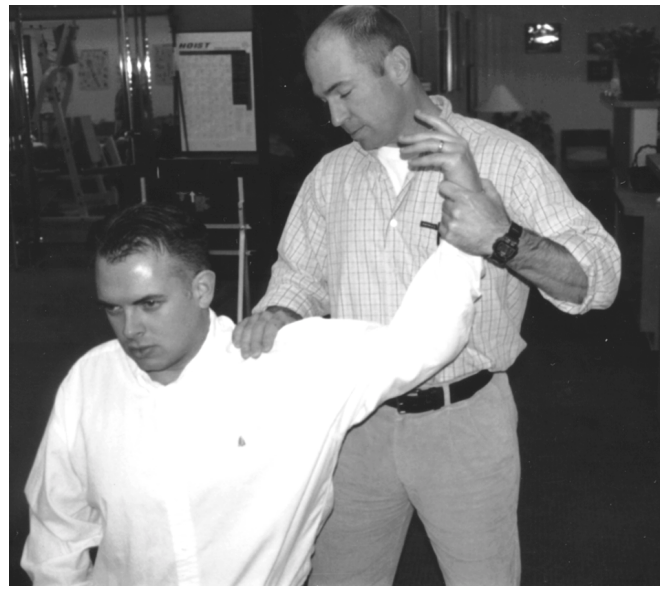



Fig. 6: Provocation test for tears of the superior labrum. Adapted from Mimori K, Muneta T, Nakagawa T, Shinomiya K. A new pain provocation test for superior labral tears of the shoulder. *Am J Sports Med* 1999;27:137-142.

Treatment

There are outcome studies available with regards to surgical intervention. However, surgical intervention lies outside of the scope of this article. Research on the outcomes of conservative treatment protocols is, to my knowledge, not available. We will have to rely on the few suggestions that have been published^{18,30,36} in combination with a common sense approach based on the information discussed previously.

At this point, it is important to summarize possibly clinically relevant information. Cooper et al¹⁴ found the superior and antero-superior portions of the labrum to be less vascularized than the posterior and inferior portions; they also found vascular penetration to be limited to the peripheral attachment of the labrum to the joint capsule. Burkhart and Fox³⁷ stated that this distribution of vascularity in the central versus peripheral part of the labrum may affect decisions regarding excision versus repair; they compared these injuries in the different parts of the labrum with lesions in the avascular and vascular portions of the meniscus in the knee. Extending this assumption to conservative therapy, it seems to make little sense to attempt to conservatively treat a tissue that is not or poorly vascularized and, therefore, has no or only limited healing potential. Clinical tests and diagnostic imaging may give us an indication as to location and healing potential of the tissue. Most type II and IV, and some type III SLAP-lesions do not appear to be an indication for conservative therapy. Further extending the analogy with the meniscus, if the lesion is in a vascularized portion of

the labrum, an important therapeutic goal would be to maximize healing potential by decreasing shear forces on the injured tissue. These shear forces have been hypothesized to play a role in producing the labral lesion^{5,10} and would certainly seem to have the ability to reinjure the tissue and delay healing. Muscle force has been hypothesized to compress the humeral head into the labrum preventing it from rolling up and over the labrum²¹, thereby imparting shear forces to the labrum. Addressing the instability responsible for excessive shear forces would be a treatment priority.

Cordasco et al²⁸ bluntly stated that SLAP-lesions are the result of instability and should not be considered isolated lesions. Partly supporting this view, Bey et al¹⁰ did find a greater incidence of type II-lesions in shoulders with an inferior subluxation. Liu et al³⁰ stated that it is as of yet unclear whether labral tears result from a pre-existing instability or whether they are sustained at the time of the original injury that also leads to the instability. They questioned whether the pain most patients with a SLAP-lesion complain about is the result of the labral tear or the instability. The authors suggested an intensive 3-month program of activity modification, non-steroidal anti-inflammatory medications, and physical therapy (PT) for patients with mild instability and labral tears. The PT program is described as PROM, followed by AROM of the shoulder, strengthening of the RC and scapular stabilizers, and finally functional and sport-specific activities. Patients who experience relief are thought to have had pain as a result of the instability; the source of pain in those refractory to treatment is hypothesized to be the

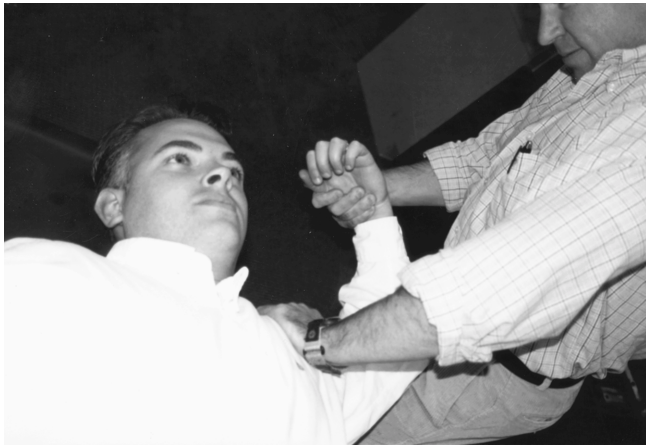


Fig. 7: Biceps load test. Adapted from Kim S, Ha K, Han K. Biceps load test: A clinical test for superior labrum anterior and posterior lesions in shoulders with recurrent anterior dislocations. Am J Sports Med 1999;27:300-3.

labral tear. SLAP-lesions have been shown to increase translation in multiple directions, most notably anteriorly and inferiorly, in the lower to midrange of scapular plane abduction, without directly creating overt instability²⁴. Indirectly, however, SLAP-lesions may cause antero-inferior instability, as reduced mechanical efficiency of the long head of the biceps in type II-lesions has been shown to increase IGHL strain²⁵. The role of the biceps as an anterior stabilizer has been shown to increase in the presence of anterior instability²³. It seems to make good clinical sense to address issues of RC and scapulothoracic muscle endurance, strength, and coordination to compensate for a compromised labral-bicipital-complex.

All capsulolabral injuries compromise glenohumeral stability to some extent. An incompetent long head of the biceps has been shown to result in increased superior translation with scapular plane abduction²²; this may directly stress the RC via mechanical attrition due to impingement but also indirectly as the RC attempts to control glenohumeral arthrokinematics with a decreased biceps contribution³⁰. Increased stress to the RC may explain the high incidence of concomitant RC symptoms in patients with SLAP-lesions. Addressing the RC with anti-inflammatory modalities, joint and soft tissue mobilization, and exercise to increase RC and scapular muscle endurance, strength, and coordination should be part of the treatment program in the case of RC involvement.

Anatomical studies have shown the intimate relationship between the tendon of the long head of the biceps and the superior labrum^{14,19,20}. Indeed, some studies found that in the majority of shoulders the tendon inserted almost exclusively into the labrum¹⁹. Biceps contraction has

been found to lift the labrum off the glenoid in case of superior labrum lesions⁴. Williams et al³⁶ stated that we should either avoid or carefully monitor biceps strengthening in patients with SLAP-lesions: traction to the healing superior labrum with the risk of subsequent re-injury may outweigh the need to maintain the biceps as a glenohumeral stabilizer. Exercise for RC and scapulothoracic muscles to compensate for lacking biceps function may be indicated rather than outright biceps strengthening.

Conclusion

Rehabilitation potential by means of physical therapy interventions seems very limited for most type II and IV, and for some type III SLAP-lesions. The main role for the physical therapist in this type of lesion appears to be the correct identification of these patients, followed by a referral for a surgical opinion. This review of the mechanisms of injury and the complaints associated with SLAP-lesions should help the physical therapist to identify patients at risk for this type of lesion. The SLAP prehension test^{29,34} has shown greater sensitivity for identifying type II-IV SLAP-lesions. The active compression test³², the provocation test for tears of the superior labrum³¹, and the biceps load test³³ are based on a similar biomechanical rationale. They may, therefore, also be useful for distinguishing between stable and unstable SLAP-lesions.

The relationship between rotator cuff lesions and glenohumeral instability on the one hand, and SLAP-lesions on the other hand is equivocal. It is unclear if the SLAP-lesion causes the other lesions, or whether the SLAP-lesion is secondary to these lesions. Their interdependence appears to be more complex than a straightforward cause and effect relationship. Increasing glenohumeral stability by addressing rotator cuff and capsuloligamentous strain and their causative factors, other than the SLAP-lesion, and by strengthening rotator cuff and scapulothoracic musculature may be a valid therapeutic approach in type I and some type III SLAP-lesions. It may also be the only therapeutic option in those patients with contra-indications to surgical intervention. Biceps strengthening, which normally may be part of the treatment for rotator cuff lesions and instability, should be done with caution, as it may aggravate and progress existing SLAP-lesions.

Acknowledgement

I would like to thank Sam Kegerreis, PT, ATC, and Jim Shiley for their help in collecting the references; Henri van Maasackers, PT, and Harry Hoevenaars, MD, for first introducing me to the concept of SLAP-lesions; and Michael Choate, PT, and Tony Guyette, ATC, from North Lake Physical Therapy and Rehabilitation, Lake Oswego, OR, for posing for the pictures in this article. ■

REFERENCES

1. Spalteholz W, Spanner R. *Handatlas der Anatomie des Menschen, erster Teil: Bewegungsapparat*. 16th ed. Amsterdam: Scheltema & Holkema NV, 1960.
2. Glasgow SG, Bruce RA, Yacobucci GN, Torg JS. Arthroscopic resection of glenoid labral tears in the athlete: A report of 29 cases. *Arthroscopy* 1992;8:48-54.
3. Kibler WB. Specificity and sensitivity of the anterior slide test in throwing athletes with superior glenoid labral tears. *Arthroscopy* 1995;11:296-300.
4. Andrews JR, Carson WG, McLeod WD. Glenoid labrum tears related to the long head of the biceps. *Am J Sports Med* 1985; 13:337-41.
5. Snyder SJ, Karzel RP, Del Pizzo W, Ferkel RD, Friedman MJ. SLAP Lesions of the shoulder. *Arthroscopy* 1990;6:274-79.
6. Snyder SJ, Banas MP, Karzel RP. An analysis of 140 injuries to the superior glenoid labrum. *J Shoulder Elbow Surg* 1995;4:243-48.
7. Maffet MW, Gartsman GM, Mosely B. Superior labrum-biceps tendon complex lesions of the shoulder. *Am J Sports Med* 1995; 23:93-98.
8. LaBan MM, Gurin TL, Maltese JT. Slip of the lip-tears of the superior glenoid labrum anterior to posterior (SLAP) syndrome: A report of four cases. *Am J Phys Med Rehabil* 1995;74:448-52.
9. Field LD, Savoie FH. Arthroscopic suture repair of superior labral detachment lesions of the shoulder. *Am J Sports Med* 1993; 21:783-90.
10. Bey MJ, Elders GJ, Huston LJ, Kuhn JE, Blasler RB, Soslowsky LJ. The mechanism of creation of superior labrum, anterior and posterior lesions in a dynamic biomechanical model of the shoulder: The role of inferior subluxation. *J Shoulder Elbow Surg* 1998;7:397-401.
11. Taylor M, Fruth S, Kegerreis S. The glenoid labrum: Basic science and clinical correlation. *Journal of Sports Rehabilitation* 1995; 4:42-53.
12. Mileski RA, Snyder SJ. Superior labral lesions in the shoulder: Pathoanatomy and surgical management. *J Am Acad Orthop Surg* 1998;6:121-31.
13. Prodromos CC, Ferry JA, Schiller AL, Zarins B. Histological studies of the glenoid labrum from fetal life to old age. *J Bone Joint Surg* 1990;72A:1344-48.
14. Cooper DE, Arnoczky SP, O'Brien SJ, Warren RF, DiCarlo E, Allen AA. Anatomy, histology, and vascularity of the glenoid labrum. *J Bone Joint Surg* 1992;74A:46-52.
15. Kreitner KF, Botchen K, Rude J, Bittinger F, Krummenauer F, Thelen M. Superior labrum and labral-bicipital complex: MR imaging with pathologic-anatomic and histologic correlation. *Am J Roentgenol* 1998;170:599-605.
16. Wilk KE, Arrigo CA, Andrews JR. Current concepts: The stabilizing structures of the glenohumeral joint. *J Orthop Sports Phys Ther* 1997;25:364-79.
17. Smith DK, Chopp TM, Aufdemorte TB, Witkowski EG, Jones RC. Sublabral recess of the superior glenoid labrum: Study of cadavers with conventional nonenhanced MR imaging, MR arthrography, anatomic dissection, and limited histologic Examination. *Radiology* 1996;201:251-56.
18. Schmitz MA, Ciullo J. The recognition of superior labrum anterior-posterior (SLAP) lesions in the shoulder. *Medscape Orthopedics & Sports Medicine* 1998;2(6).
19. Pal GP, Bhatt RH, Patel VS. Relationship between the tendon of the long head of the biceps brachii and the glenoid labrum in humans. *Anat Rec* 1991;229:278-80.
20. Vangsness CT, Jorgenson SS, Warson T, Johnson DL. The origin of the long head of the biceps from the scapula and glenoid labrum. *J Bone Joint Surg* 1994;76B:951-54.
21. Howell SM, Galinat BJ. The glenoid-labral socket. *Clin Orthop* 1989;243:122-25.
22. Warner JJ, McMahon PJ. The role of the long head of the biceps brachii in superior stability of the glenohumeral joint. *J Bone Joint Surg* 1995;77A:366-72.
23. Itoi E, Kuechle DK, Newman SR, Morrey BF, An KN. Stabilising function of the biceps in stable and unstable shoulders. *J Bone Joint Surg* 1993;75B:546-50.
24. Pagnani MJ, Deng XH, Warren RF, Torzilli PA, Altchek DW. Effect of lesions of the superior portion of the glenoid labrum on glenohumeral translation. *J Bone Joint Surg* 1995;77A:1003-10.
25. Rodosky MW, Harner CD, Fu FH. The role of the long head of the biceps muscle and superior glenoid labrum in anterior stability of the shoulder. *Am J Sports Med* 1994;22:121-30.
26. Glousman R, Jobe FW, Tibone J, Moynes D, Antonelli D, Perry J. Dynamic electromyographic analysis of the throwing shoulder with glenohumeral instability. *J Bone Joint Surg* 1988;70A:220-26.
27. Snyder SJ. Review of "Case report: Arthroscopic repair of a type IV SLAP lesion-the red-on-white lesion as a component of anterior instability." *Arthroscopy* 1993;9:494-96.
28. Cordasco FA, Steinmann S, Flatow EL, Bigliani LU. Arthroscopic treatment of glenoid labral tears. *Am J Sports Med* 1993; 21:425-30.
29. Berg EE, Ciullo JV. A clinical test for superior glenoid labral or "SLAP" lesions. *Clin J Sports Med* 1998;8:121-23.
30. Liu SH, Henry MH, Nuccion SL. A prospective evaluation of a new physical examination in predicting glenoid labral tears. *Am J Sports Med* 1996;24:721-25.
31. Mimori K, Muneta T, Nakagawa T, Shinomiya K. A new pain provocation test for superior labral tears of the shoulder. *Am J Sports Med* 1999;27:137-142.
32. O'Brien SJ, Pagnani MJ, Fealy S, McGlynn SR, Wilson JB. The active compression test: A new and effective test for diagnosing labral tears and acromioclavicular joint abnormality. *Am J Sports Med* 1998;26:610-13.
33. Kim S, Ha K, Han K. Biceps load test: A clinical test for superior labrum anterior and posterior lesions in shoulders with recurrent anterior dislocations. *Am J Sports Med* 1999;27:300-3.
34. Berg EE, Ciullo JV. The SLAP lesion: A cause of failure after distal clavicle resection. *Arthroscopy* 1997;13:85-89.
35. Magee DJ. *Orthopaedic Physical Assessment*. 2nd ed. Philadelphia, PA: WB Saunders Company, 1992.
36. Williams RJ, Levinson M, Warren RF. SLAP lesions: Structure, function, injury, and treatment. In: Wilk KE, ed. *Recognition and Treatment of Shoulder Joint Injuries*, 1999 Sports Physical Therapy Home Study Course. LaCrosse, WI: Sports Physical Therapy Section, APTA, 1999.
37. Burkhart SS, Fox DL. Case Report: Arthroscopic repair of a type IV SLAP lesion-the red-on-white lesion as a component of anterior instability. *Arthroscopy* 1993;9:488-92.